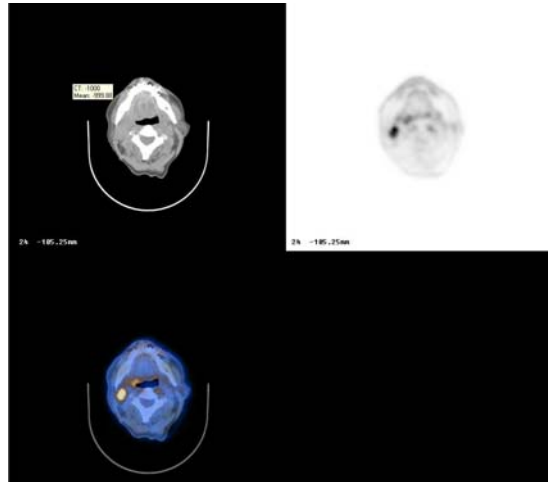


PETIMAGING

INTEGRATED PET/CT SCANNING CASE STUDY N^o 44

Head and Neck Cancer: Unknown Primary



A 72 year old man discovers a mass in his neck, and a fine needle aspiration reveals squamous cell carcinoma. An MRI is unable to locate the primary cancer. PET/CT is ordered for staging and identifies the primary cancer in the right tonsil. An unexpected metastatic lesion is found in the L1 vertebral body. Due to this metastatic lesion, the patient is spared surgery and begins chemotherapy. A PET/CT conducted after the chemotherapy demonstrates a complete response.

