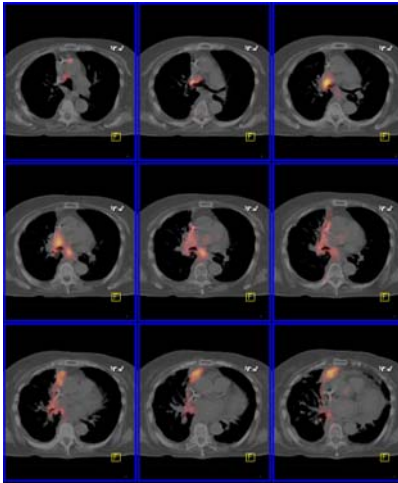


PETIMAGING

INTEGRATED PET/CT SCANNING CASE STUDY N^o 45

Non-Small Cell Lung Cancer: Recurrence



A 64 year old female with a history of NSCLC complains of rib pain. A bone scan reveals degenerative changes with “no convincing evidence for metastasis”. A chest CT demonstrates extensive scarring, pleural effusion and 1 enlarged lymph node. Thoracentesis is negative for malignancy. PET/CT ordered for restaging reveals extensive metastatic disease including L-5 and left iliac bone metastases, a right hilar mass, a right celiac lymph node and right pleural effusion.

