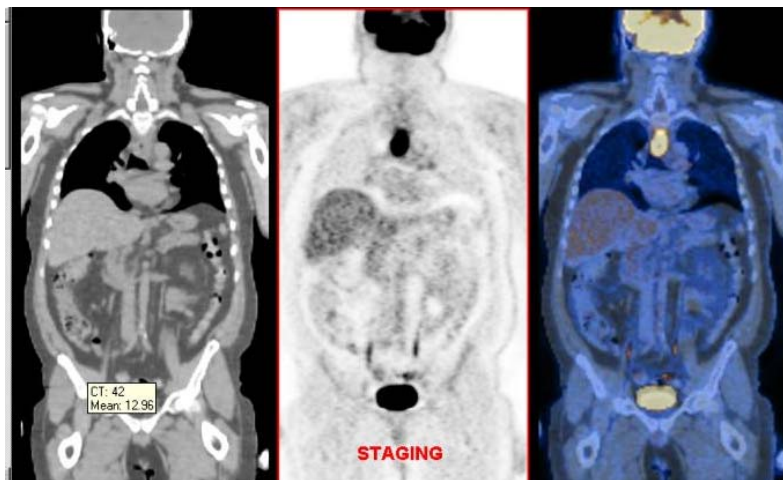


PETIMAGING

INTEGRATED PET/CT SCANNING CASE STUDY N^o 49

Assessing Therapy Response: Esophageal Cancer

A 46 year old male has a PET/CT scan to stage his recently diagnosed esophageal cancer. PET/CT shows hypermetabolic activity in the known primary tumor at the level of the aortic arch. In addition, lymph node metastases in the left upper chest are identified.



The patient has a post-therapy PET/CT which reveals a complete resolution of the previously identified disease with no sign of active cancer.

