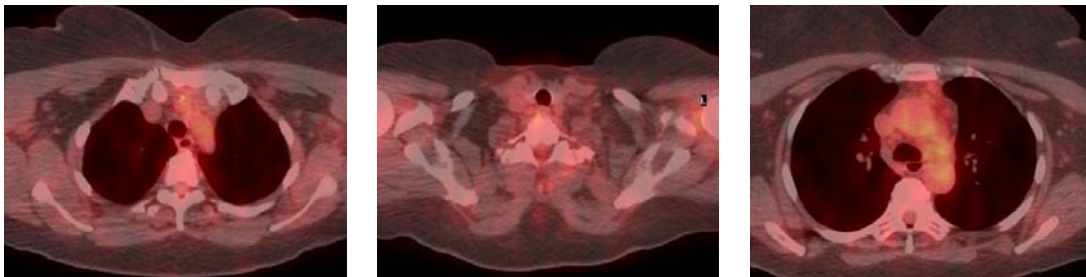


PETIMAGING

INTEGRATED PET/CT SCANNING CASE STUDY N° 91

Non-Hodgkin's Lymphoma- Guiding the Course of Therapy

A 65 year old female diagnosed with Non-Hodgkin's Lymphoma undergoes treatment with Rituxan resulting in a complete response to therapy. In January PET/CT identifies recurrent disease in the cervical, supraclavicular, mediastinal, hilar, retroperitoneal, iliac, and inguinal lymph nodes. Patient is treated with Bexxar, and a restaging PET/CT demonstrates a complete response.



Three months later, the patient begins to show signs of recurrent lymphoma. PET/CT reveals extensive hypermetabolic lymphadenopathy in the right external iliac, right jugular, bilateral submandibular, supraclavicular, mediastinal, and paraaortic lymph nodes. CHOP and Rituxan are administered for recurrence.

